

CLINICAL CASE  
KODAK 9000 3D Extraoral Imaging System

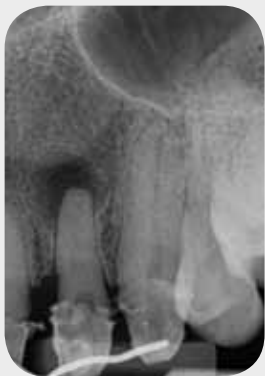# Advantages of Cone Beam Computed Tomography for Proper Endodontic Therapy

## Case Overview

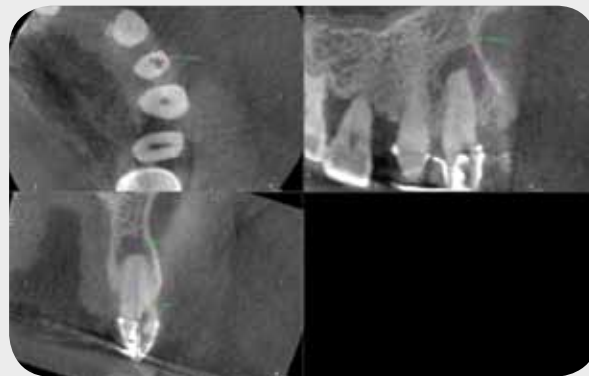
A 63-year-old Caucasian male of normal health presented to the office as an emergency. His dentist observed an apical lesion on the radiograph and attempted to perform root canal treatment. Upon failure to find the canal he placed a temporary filling and referred the patient for treatment.

Examination revealed: #10 part of temporary splint, negative response to vitality testing, and no sensitivity to percussion, palpation or bite tests. No swelling or sinus tract existed. Periodontal exam displayed no pocketing greater than 3 mm and minimal recession. Previous access sealed with temporary material.

Conventional 2D radiograph exhibits circumscribed apical periodontitis, horizontal bone loss and normal adjacent structures. Canal is visible on 2D image. 3D CBCT scan was used to determine location of canal in relationship to current access. Axial and sagittal views assisted in locating canal and properly treating the root canal.



Initial Periapical



CBCT to Determine Canal Location and Extent of Recent Access Opening

## Treatment Plan

The tooth was measured and the access was regained, the case was completed, and a post preparation was left for the dentist to place a post. A six month recall will be taken to ensure proper healing.



**Dr. Randolph Todd, DMD**  
New York, NY

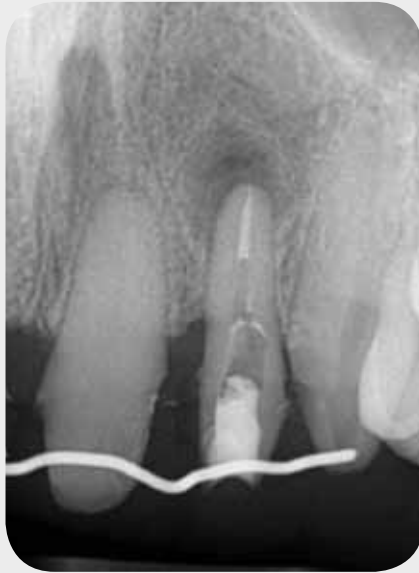Dr. Todd earned his Doctor of Dental Medicine (DMD) in 1977 from Tufts University School of Dental Medicine. After he completed his General Practice Residency at North Shore University Hospital, then a Cornell University Affiliate, he received his Certificate in Endodontics from New York University College of Dentistry and later became a Board Certified Diplomate of the American Board of Endodontics.

Dr. Todd has been in private practice for 32 years and limits his practice to Conventional and Microsurgical Endodontics. He also has concurrent experience in teaching at General Practice Residency and Specialty Programs. Dr. Todd was selected as a Scientific Editor for the JOE, a mentor for the ABE Diplomate Exam and a coordinator for the Columbia University and College of Diplomate ABE Board Review Course in 3/2010.

He is a member of the American Association of Endodontics, American Board of Endodontics, College of Diplomates, NY State Endodontic Society, 1st District Dental Society, American Dental Association, Tufts University School of Dental Medicine Alumni Association and New York University College of Dentistry Alumni Association.

## KODAK Product

- KODAK 9000 3D System



Post-Preparation

## Testimonial

One of the unique features of the Kodak 9000 3D system is the ease with which you can realign the viewing plane with the long access of the tooth. This is accomplished in the "Oblique" viewing mode and provides the observer with an appropriate angle to interpret the local anatomy. This manipulation facilitates interpreting the number of canals within a root when viewing the axial slices and measuring the length of a root from the sagittal or frontal slices. Both practices are significant chair time savers.

Observation of the root morphology, on all slices, provides information that can assist the dentist with the instrumentation phase of Endodontics. Deep grooves detected on the perimeter of roots, (reportedly seen 83% of the time on the lingual surface of the buccal root of the maxillary 1st bicuspid) could result in a strip perforation if not avoided and radiographically observed on a CBCT before starting treatment. Calcified canals, a frequently encountered problem, are demystified when using cone beam technology. The traditional "hunting" to find the opening of the canal is no longer a problem. Canals not previously observable on 2D radiographs are easily discernible and treated with the assistance of the CBCT.

Offering an improved level of care to both the patient and the referring practices is consistent with all practice building approaches. PracticeWorks software makes sharing the images easy. After my clinical exam I sit down with the patient and review the scan, then select the images I want to send to the referring practice and either print or email them. In those cases where the dentist personally wants to review the entire volume, I burn the images to a disk and send it back with the patient. This technology is a win-win for patient care and improved diagnostic technique.