

KODAK 9000C 3D Panoramic and Cephalometric System

Impacted Canine and Lateral Incisor Root Interference: Who Wins?

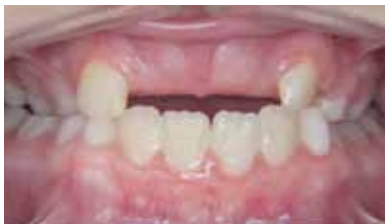Robert L. Waugh, DMD, MS, and Assistant Professor of Orthodontics, Medical College of Georgia

Case Overview

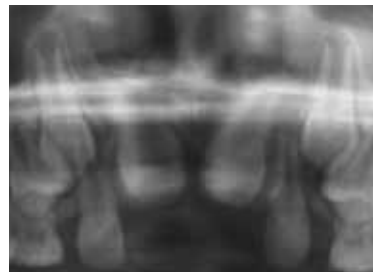Bilateral unerupted permanent maxillary central incisors in a 10 year-old male. This 10 year 3 month old boy was brought to our private orthodontic practice by his mother with a chief complaint of “two missing front teeth.” She reported that the child had fallen when he was three years old, hitting and avulsing his primary maxillary central incisors.

The gingiva overlying the unerupted teeth was extremely fibrotic; however, the outline of the teeth could be discerned. Our preliminary exam included a panoral screening radiograph, which did not reveal anything of note – all permanent teeth were present. The initial findings suggested blocked eruptions due to fibrotic gingival tissue or to overlying bone related to premature tooth loss.

In preparation for orthodontic care, the incisal edges were uncovered using topical anesthesia and a diode laser. On clinical evaluation three months later, the tissue was well-healed, but the teeth remained unerupted despite the procedure.



Outline of the maxillary central incisors seen beneath the gingiva



CONVENTIONAL PAN (cropped): Two supernumerary maxillary centrals perfectly occluded by permanent central incisors

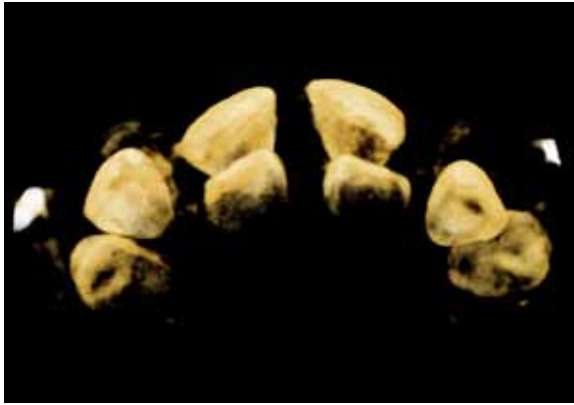


Robert L. Waugh, DMD, MS, and Assistant Professor of Orthodontics, Medical College of Georgia

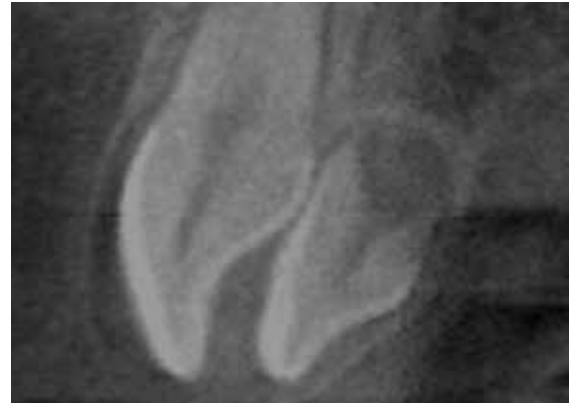
Dr. Bob Waugh, a native Georgian, has been practicing in the Athens area since 1989. He received his BS degree from Mercer University in 1983. Dr. Waugh then became the Medical College of Georgia School of Dentistry's first combined degree graduate in 1987, earning both his D.M.D. and an M.S. in Oral Biology. Upon graduation, he was elected to Omicron Kappa Upsilon, the national dental honor society. Dr. Waugh attended his residency in orthodontics at the Baylor College of Dentistry, earning his certificate of specialization in 1989 and becoming a Diplomate of the American Board of Orthodontics in 2000.



Clinical Case Study



KODAK 9000C System "3D Scene View" occlusal orientation:
Cusp tips of supernumerary teeth clearly seen



KODAK 9000C System Sagittal Cut Plane View

A definitive 3D radiographic examination using the Kodak 9000C system revealed bilateral developing supernumerary teeth immediately lingual to the centrals and not evident on either the panoramic or the cephalometric radiograph. The patient was referred to an oral surgeon for evaluation and subsequent extraction of the supernumerary teeth.

Testimonial

Because panoramic radiographs are historically screening aids, 3D images for initial radiographic diagnostics would have allowed for more efficient care through a more immediate referral to the oral surgeon.

Additionally, had 3D images not been available, orthodontic treatment would have proceeded and probably would have been influenced by the presence of these two fully-formed and undetected teeth.

