

KODAK 9000 3D Extraoral Imaging System

Endosseus Implant Placement

Dr. T Michael Murphy, Oral and Maxillofacial Surgery

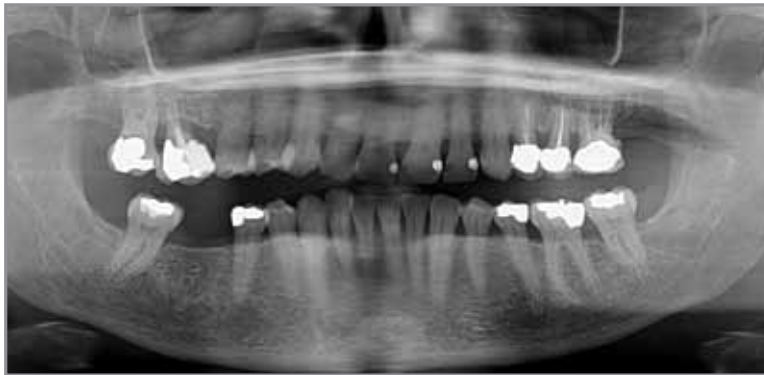
Case Overview

52-year-old female needed endosseous implant placement evaluation. Kodak 9000 3D system revealed viability of molar form implant placement with simultaneous bone graft. The panoramic image reveals adequate vertical bone in which to place an endosseous implant, but allows no interpretation of the horizontal bone dimension. Clinical observation is equivocal, but suggests there may be sufficient lingual bone height and positional adequacy. It is unknown whether an implant can be placed without a bone graft, with a bone graft, or not at all.

The 3D images clearly show adequate lingual bone height and position, but inadequate buccal bone. Using the implant placement, nerve canal, and bone measurement tools, it becomes apparent a stabile molar form implant can be placed with a simultaneous bone graft.

Dr. T Michael Murphy, Oral and Maxillofacial Surgery

Dr. Murphy owns a private practice in Marion, OH specializing in oral and maxillofacial surgery. He graduated from the Ohio State University College of Dentistry and completed a fellowship in oral pathology and oral surgery and a residency in oral and maxillofacial surgery from OSU. He was an assistant clinical professor at OSU for 21 years.

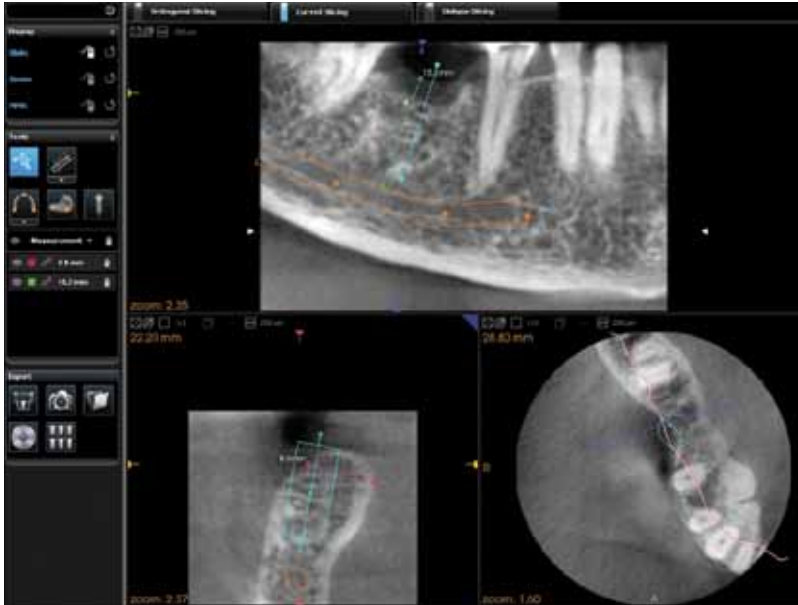


Panoramic image

Clinical Case Study



Clinical Case Study



3D image for implant placement

Testimonial

Before installation of the Kodak 9000 3D system, this patient would have been told the implant might be placed but with three different post-surgical expectations:

1. The implant might be placed without additional complication.
2. The implant might be placed with the necessity of a bone graft.
3. The implant might not be able to be placed at all, and only the bone graft would be accomplished.

These statements would lead to significantly different costs and overall treatment time estimates, possibly resulting in loss of the case. If treatment was accepted under these conditions, appointment time scheduling would have to include enough time for the most lengthy of the three options.

Since installation of the Kodak 9000 3D system, this scenario no longer happens. Bone size and position can be determined to the nearest 0.1mm, virtual implants of almost infinite height and width can be placed and positioned, and the mandibular canal can be observed.

What made this machine even more appealing was its ability to fit the space where our former panoramic unit existed with minimal alterations. The little remodeling necessary proved to be an enhancement to our office and the patient's opinions of our technological dedication.